

Medical Management of Acute Bacterial Sinusitis

Friday, June 17, 2011
Madrid I ~ 1:25pm - 2:10pm

Tom Nunn, DO
9416 S Florence Ave
Tulsa, OK 74137
Tel: (918) 459-8824
Fax: (918) 307-2239
Email: officemgr@enttulsa.com

Objectives

- Diagnosis of bacterial sinusitis
- Learn new treatment options for sinusitis

Faculty Disclaimer

The OAFP has selected all faculty appearing in this program. According to OAFP policy, all relationships between speakers and proprietary entities will be disclosed.

*The speakers returned a disclosure indicating that they or an immediate family member **does not** a significant financial interest in or affiliation with a commercial supporter of this educational activity and/or with the manufacturer(s) of commercial products and/or providers of any commercial services discussed in this educational presentation/material.*

They listed (if applicable) commercial enterprises and the nature of relationship with each, e.g. research grants, stock or bond holdings, speakers' bureau, employment, ownership or partnership, consulting fees, other remunerations (honoraria, travel expenses):

Corporate Organizations

None

Financial Interests/Affiliations

The content of this/these material(s)/presentation(s) in this CME activity **will not** include discussion of unapproved or investigational uses of products or devices.

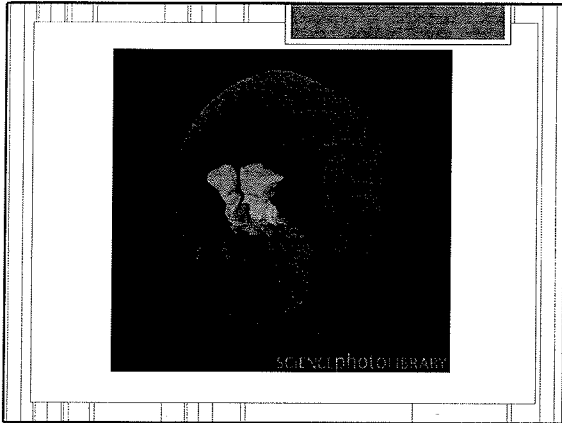Sinusitis
Thomas V. Nunn, D. O.

ANATOMY

- There are four paired paranasal sinuses, the maxillary, ethmoid, frontal and sphenoid sinuses
- "Anterior" and "posterior" sinuses
- Lining of the sinuses is pseudostratified, columnar epithelium (respiratory epithelium) which is continuous with the nasal epithelium

ANATOMY (continued)

- The mucosa secretes a mucous which traps bacteria
- The mucous is naturally extruded through sinus ostia to be expectorated or swallowed
- The drainage of the maxillary and frontal sinuses follows a circular pattern through the natural ostia



The Ethmoid Sinus

- Appear as evaginations of the lateral nasal wall around the third month of fetal gestation
- Are present at birth, adult size by age 12
- Are separated by the ground (basal) lamella into the anterior and posterior ethmoids, which drain into the middle and superior meatus, respectively

The Ethmoid Sinus, continued

- Consist of vertical and horizontal plates
- The vertical plate is divided into two portions, the perpendicular plate of the ethmoids and the crista galli
- The horizontal plate is known laterally as the fovea ethmoidalis and medially as the cribriform plate
- Medially is the lamina papyracea

The Ethmoid Sinus, continued

- Blood supply is from both the external and internal branches of the carotid, through the sphenopalatine and the anterior and posterior ethmoidal arteries
- Innervation is from V2 and V3

The Maxillary Sinuses

- The largest sinus
- Pyramidal shaped with apex near zygomatic arch
- In child, inferior border near nasal floor. In adult, 1 cm below nasal floor
- Floor over maxillary dentition, which is often thin and dehiscant over tooth roots

Maxillary Sinuses, Continued

- The infraorbital nerve runs along roof, and is often dehiscant. At risk during antral procedures
- Sinus ostia located anteriorly in the middle meatus
- Accessory ostia are usually more posterior and are a sign of chronic disease

Maxillary Sinus, continued

- Blood supply is from divisions of the maxillary artery
- Innervation is via V2
- Postganglionic sympathetic fibers are from VII via the sphenopalatine ganglion and the greater superficial petrosal nerve

Frontal Sinus

- Begins as evagination of the anterior nasal capsule around the fourth month of development
- Rarely present at birth; usually not visible until age 2
- Great variability in size; congenitally absent in 5%

Frontal Sinus, continued

- Drains into the frontal recess in the middle meatus near the upper portion of the infundibulum
- Like the maxillary sinuses, have circular mucociliary clearance
- Blood supply from the supraorbital and supratrochlear arteries, innervation from nerves of the same name

Sphenoid Sinuses

- Began as outpuchings of the superior nasal vault around the fourth month of gestation
- Rarely present at birth, usually seen around age 4
- Drain into the superior meatus in the sphenothmoidal recess
- Ostia of variable size

Sphenoid Sinuses, continued

- The optic nerve lies superiorly
- The pons lies posteriorly
- The cavernous sinus is lateral, along with CNIII, IV and VI and the carotid artery
- The carotid artery is dehiscent in 50% of specimens

Sphenoid Sinuses, continued

- Blood supply from both the internal and external carotid arteries via the sphenopalatine (floor) and the posterior ethmoidal arteries (roof)
- Innervation from V2 and V3

Pathophysiology of Sinusitis

- Lined by respiratory epithelium
- Mucous blanket is in two layers: a superficial viscous layer and an underlying serous layer.
- Cilia beat in the serous layer, moving the blanket towards the natural ostia
- Normal function depends on patent ostia, ciliary function and quality of mucous

Pathophysiology of Sinusitis, continued

- Most important pathologic process in disease is obstruction of natural ostia
- Obstruction leads to hypooxygenation
- Hypooxygenation leads to ciliary dysfunction and poor mucous quality
- Ciliary dysfunction leads to retention of secretions

Pathophysiology of Sinusitis, continued

- Local factors can impair ciliary function. Cold air "stuns" the epithelium, resulting in retained secretions. Dry air dessicates the blanket.
- Anatomical factors, ie, polyps, tumors, foreign bodies and rhinitis, block the ostia
- Kartagener's Syndrome (immotile cilia syndrome)

Pathophysiology of Sinusitis, continued

- Acute sinusitis is defined as disease lasting less than one month
- Subacute sinusitis is defined as disease lasting 1 to 3 months
- Chronic sinusitis is defined as disease lasting more than three months, and is usually due to inadequately treated acute or subacute disease

Pathophysiology of Sinusitis, continued

- Acute sinusitis and subacute sinusitis are treated medically
- Chronic sinusitis is considered irreversible by medical therapy alone, and it is currently believed oxygenation of the sinuses through opening of the ostia is the primary treatment

History and Physical Exam

- Acute sinusitis presents as pain over infected areas, with or without headache
- Pain to palpation is common with anterior sinusitis, but is usually absent with the posterior sinuses
- Posterior sinuses present as bitemporal or vertex headaches
- Fever, malaise, nasal discharge present

History and Physical, continued

- Chronic sinusitis usually seen with a mucopurulent discharge, but fever is usually not present
- Acute sinusitis is often imposed on chronic disease
- Note any facial edema, tenderness, mucosal edema, septal perforations and deviations

History and Physical

- Diagnosis is primarily clinical, but radiographs can be used
- Transillumination of the sinuses can sometimes be used, but due to differences in sinus size and patency, these tests are not reliable
- Antral lavage can be performed in select cases where the diagnosis is in doubt

Acute Bacterial Sinusitis

- Acute sinusitis can be thought of as an abscess or empyema
- Cornerstone is drainage and antibiotics
- Drainage is usually medical with topical decongestants and sometimes antihistamines
- In rare cases where medical treatment fails, surgical drainage may be required


Acute Rhinosinusitis

- Decongestants
 - Topical
 - Systemic
- Analgesics
- Reserve antibiotics
 - For 10 days
 - Unless severe, complications become evident, or infection over 10 days (most viral illnesses will have subsided by then).

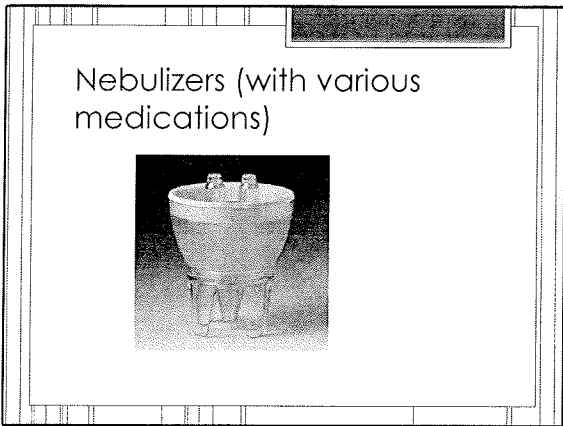
Acute Bacterial Sinusitis, continued

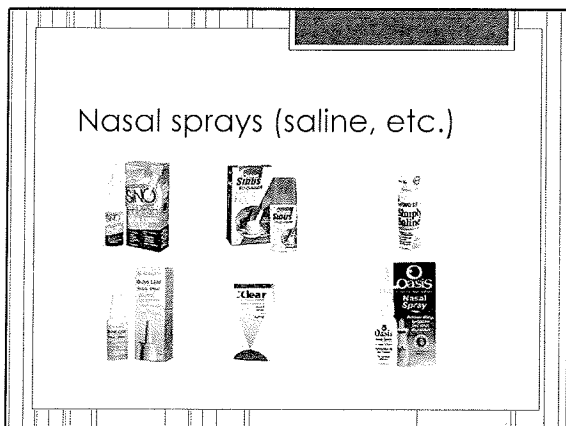
- S. pneumo, H. flu and M. carrarhalis
- High dose amoxicillin or amoxicillin/clavulinate initial choice. Alternatives include cefdinir, cefpodoxime, and cefprozil.
- Azithromycin and levofloxacin also effective.
- Surgical drainage sometimes required for failures on appropriate antibiotics and topical decongestants

Neti Pot









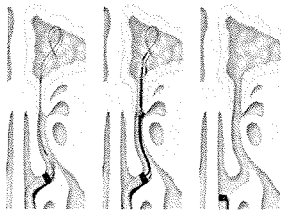
IV Antibiotics

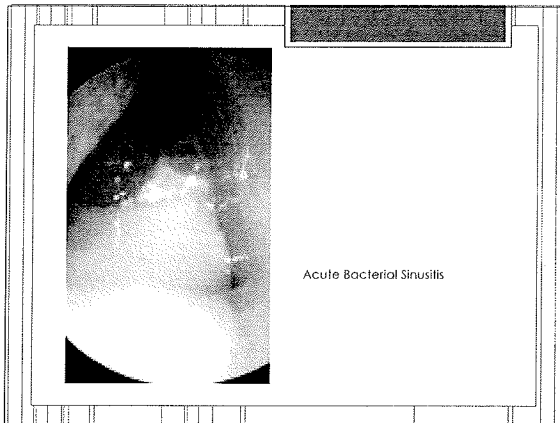
- Culture driven
- Can administer much higher antibiotic dosages
- PICC line
- No need for hospitalization in most cases
- Useful for recalcitrant cases

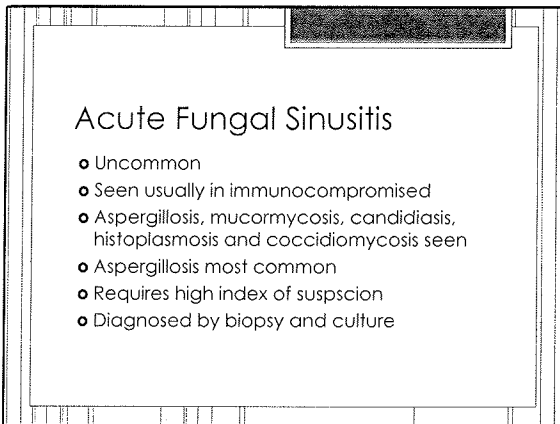
Acute Bacterial Sinusitis, continued

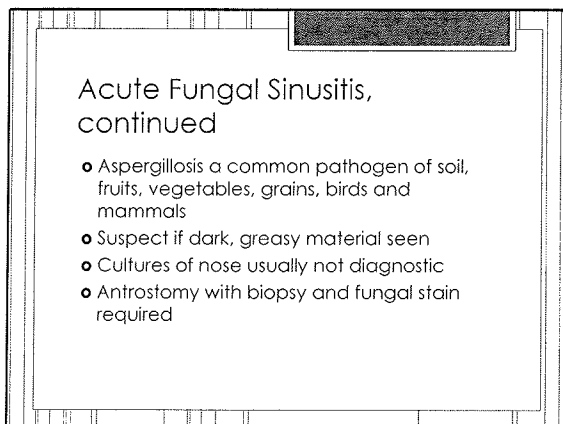
- Maxillary sinuses are surgically drained by antral lavage, inferior meatal windows or middle meatal windows
- Frontal sinuses are drained by trephination, and a drain is left in place and irrigated twice a day until drainage through the frontal duct is observed
- An ethmoidectomy drains the ethmoids

Balloon Sinuplasty









**Acute Fungal Sinusitis,
continued**


- Noninvasive Aspergillosis seen as fungal ball, usually in maxillary sinus
- Invasive aspergillosis can invade bone.
- Fulminant aspergillosis occurs in immunocompromised and invades adjacent structures
- Therapy for noninvasive forms is surgical excision followed usually by PO antifungals

**Acute Fungal Sinusitis,
continued**

- Therapy for invasive forms requires wide local debridement and intravenous ampo B
- Mucormycosis is encountered in dust and soil and enters through the respiratory tract
- The fungus invades vascular channels and causes hemorrhagic ischemia and necrosis
- Frequently fatal. 90% mortality in immunocompromised

**Acute Fungal Sinusitis,
continued**

- Ketoacidosis predisposes to mucormycosis, as the fungus thrives in acidic environments
- Initially seen as engorgement of turbinates, followed by ischemia and necrosis of the turbinates and adjacent nose
- Treated with radical surgical debridement, amphotericin B and correction of underlying immunosuppression



Complications: Mucocoeles

- Mucocoeles are chronic, cystic lesions of the sinuses lined by pseudostratified epithelium
- Expand slowly, often requiring many years
- Etiology is debated. Either due to obstruction of ostia or to simple obstruction of minor salivary gland
- 30% are idiopathic

Complications: Mucocoeles

- Frequently noted on routine CT scan of maxillary sinuses. No treatment is required unless near natural ostia
- Frontal sinus mucocoeles are important to recognize as they cause proptosis and even blindness
- Therapy involves obliteration of sinus

Complications: Mucoceles

- Sphenoidal and ethmoidal mucoceles are less common
- Seen with vertex headaches and deep nasal pain
- Treatment is controversial; wide drainage into the nasal vault is common

Complications: Orbital

- Orbit separated from ethmoids by thin lamina papyracea
- First indication of orbital involvement is inflammatory edema of eyelids
- Inflammatory edema of eyelids progresses to cellulitis, proptosis, chemosis and ophthalmoplegia

Complications: Orbital


- Five classifications of orbital complications
 - 1) Inflammatory edema: lid edema otherwise normal.
 - 2) Orbital cellulitis: diffuse edema
 - 3) Subperiosteal abscess: usually seen near lamina papyracea
 - 4) Orbital abscess: collection within orbit
 - 5) Cavernous sinus thrombosis:

Complications: Orbital

- Orbital complications sometimes seen in frontal sinusitis as the floor of the sinus is thin
- Known as Pott's puffy tumor
- Treatment of orbital inflammation and cellulitis is with IV antibiotics with or without sinus drainage

Complications: Orbital

- Abscesses are treated with surgical drainage and IV antibiotics
- Indications for surgical drainage include progressive orbital cellulitis, symptoms which do not resolve, abscess, loss of visual acuity



Frontal Sinus Mucocele

Also, notice displacement of the eye laterally and inferiorly.

Complications: Cavernous Sinus Thrombosis

- High mortality rate
- Usually results from retrograde transmission through valveless veins leading to the cavernous sinus
- Heralded by bilateral orbital involvement, progressive chemosis, T 105F
- Treat with drainage, IV antibiotics
- Heparin is controversial

Complications: Intracranial

- Subdural abscess, intracranial abscess, meningitis seen
- Meningitis common in children
- 1/3 to 2/3 of all subdural abscesses believed due to sinusitis
- Nuchal rigidity first symptom
- Neurosurgery consult to manage ICP, surgical drainage

Radiology

- Plain films are generally obsolete
- Exceptions include confirmation of air fluid levels in acute sinusitis, and evaluating size and integrity of the paranasal sinuses
- CT scan the study of choice in chronic sinusitis, but usually not useful in acute sinusitis, as diagnosis primarily clinical

